

Case Report

# A Clear Cell Sarcoma Case: A Diagnostic and Treatment Challenge, with a Promising Response to Trabectedin

Mar Galera<sup>a</sup> Rosa Álvarez<sup>a</sup> Marta Arregui<sup>a</sup> Miguel Paniagua<sup>b</sup>  
Ana Álvarez<sup>c</sup> Raphael Angelo González Crisostomo<sup>d</sup>  
Adriana Díazgranados<sup>e</sup> Natalia Gutiérrez<sup>a</sup> Antonio Calles<sup>a</sup> Carolina Agra<sup>f</sup>

<sup>a</sup>Medical Oncology Department, Hospital Universitario Gregorio Marañón, Madrid, Spain;

<sup>b</sup>Radiology Department, Hospital Universitario Gregorio Marañón, Madrid, Spain; <sup>c</sup>Radiation Oncology Department, Hospital Universitario Gregorio Marañón, Madrid, Spain; <sup>d</sup>De La Salle Medical and Health Sciences Institute, Governor, Damaríñas, Philippines; <sup>e</sup>Anatomic Pathology Department, Hospital Universitario Vall D'Hebrón, Barcelona, Spain; <sup>f</sup>Anatomic Pathology Department, Hospital Universitario Gregorio Marañón, Madrid, Spain

## Keywords

Clear cell sarcoma · Diagnosis · Treatment · Trabectedin · Radiotherapy · Case report

## Abstract

**Introduction:** Clear cell sarcoma (CCS) is a rare and aggressive soft tissue sarcoma. CCS is characterized by the translocation t(12;22) (q13;q12), involving the fusion of EWSR1 and ATF1 genes, and less frequently the fusion gene EWSR1-CREB1. Usually, CCSs are considered poorly responsive to conventional chemotherapy. However, trabectedin has shown activity against translocation-related sarcomas. Furthermore, preclinical results suggest that trabectedin is a promising antitumor agent for CCS, potentially inducing melanocytic differentiation. **Case Presentation:** We report the case of a challenging anatomopathological diagnosis in a patient with an aggressive metastatic CCS. Following the diagnosis of CCS, the patient experienced a clinical and radiological tumor response to trabectedin after four lines of treatment. **Conclusion:** This is a novel report of CCS treated with trabectedin that resulted in a partial response and suggests the need for further research on trabectedin as a therapeutic option for CCS.

© 2023 The Author(s).  
Published by S. Karger AG, Basel

Correspondence to:  
Mar Galera, [mar.galera.lopez@gmail.com](mailto:mar.galera.lopez@gmail.com)

## Introduction

Clear cell sarcoma (CCS), also previously referred to as “melanoma of soft parts,” is an extremely rare and aggressive malignant tumor, comprising approximately 1% of all diagnosed sarcomas [1, 2]. It often presents as a deep soft tissue mass, typically in limbs, near aponeuroses, and tendons. These tumors are characterized by melanocytic differentiation. CCS predominantly affects adolescents and young adults with an average age of 39 years old and is linked to a high tendency of developing regional or distant metastases. Nonetheless, the exact prevalence and incidence of CCSs remain uncertain [1]. This type of sarcoma is associated with either t (12;22) (q13;q12) or t (2;22) balanced chromosomal translocations, generating EWSR1-ATF1 or EWSR1-CREB1, respectively [2]. EWSR1-ATF1 occurs in up to 90% of cases [3], and this translocation results in the fusion of the 3' portion of the Ewing sarcoma oncogene (EWSR1) on chromosome 22q with the 3' portion of the activating transcription factor 1 (ATF1) oncogene on chromosome 12q, leading to the chimeric EWSR1/ATF1 transcript [4].

The treatment of choice for localized CCS is wide surgical resection, although radiation therapy is used in some situations [5]. Chemotherapy is predominantly employed in patients with metastatic disease [5] and, despite the poor evidence to support their use in CCS cases, conventional systemic therapies such as doxorubicin, gemcitabine-based chemotherapy, and pazopanib are often used [6]. Also, inhibitors of the vascular endothelial growth factor receptor (VEGFR) pathway such as sunitinib, have demonstrated a response rate of 30% ( $n = 3/10$ ) in a retrospective study. In addition, microphthalmia-associated transcription factor (MITF) has been shown to be amplified in CCS (driven by EWSR1-ATF1 translocation), which regulates MET. Because of this, other therapies that have been tested include MET inhibitors, however, with disappointing results [7, 8].

Trabectedin, a tetrahydroisoquinoline alkaloid, is the first marine-derived antineoplastic alkylating agent, which has unique anticancer properties involving DNA binding, DNA repair pathways, transcription regulation, and regulation of the tumor microenvironment [9]. There are retrospective data and two phase 2 trials that indicate that trabectedin is particularly active in sarcomas involving translocations [10–13]. Moreover, a preclinical trial suggests that trabectedin exerts antitumor effects via induction of G2/M cell cycle arrest, apoptosis, and, in part, the acceleration of melanocytic differentiation against CCS cell lines [14]. Here, we report clinical and radiological tumor response to treatment with trabectedin in a patient with an aggressive metastatic CCS after four lines of therapy. The CARE Checklist has been completed by the authors for this case report, which has been attached as supplementary material (for all online suppl. material, see <https://doi.org/10.1159/000534935>).

## Case Report

A 58-year-old female patient, without any remarkable medical history, presented in August 2019 with a left cervical mass that had grown progressively over the last 3 months. A computed tomography (CT) scan performed at another medical center, revealed a latero-cervical mass measuring 25 × 28 × 44 mm. A core needle biopsy was performed (September 2019) which led to the diagnosis of a paraganglioma. Octreotide scintigraphy was performed, and in addition to the presence of pathological hypercaptation in the left cervical region, another lesion was observed in the body of the stomach. However, gastroscopy did not reveal any endoluminal lesions nor did the gastric mucosal biopsies. In October 2019, a resection of the left laterocervical mass was performed. The initial diagnosis was an extraosseous Ewing sarcoma.

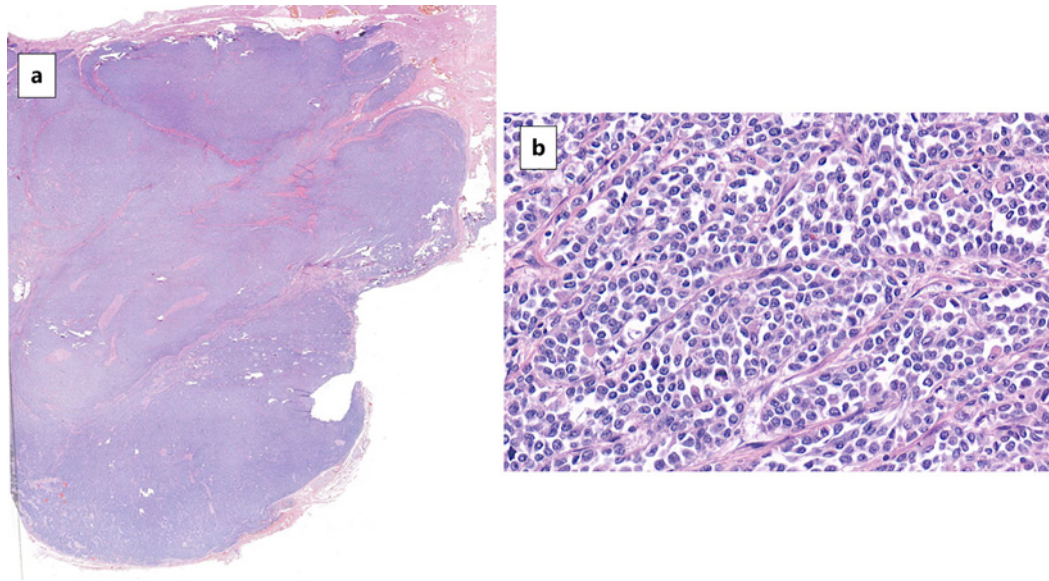
The patient was referred to our hospital, a national reference center for sarcoma, in December 2019. An anatomopathological review revealed that the patient had a tumor with oval cells with a clear eosinophilic and poorly demarcated cytoplasm, growing in nests separated by thin fibrous tracts (Fig. 1). We did not find any osteoclast-like giant cells. Immunohistochemically, it was noted to be positive for S100 and SOX10 (Fig. 2), synaptophysin and CD57, but negative for melanocytic markers staining (Melan-A, HMB45, and MITF), CD99, NKX2, CD45, CD20, CD 38, CD79a, Desmin, EMA, Myogenin, Actin ML, Enolase, C-kit, DOG1, CAM5.2, and CKAE1-AE3. An EWSR1 translocation by fluorescence in situ hybridization (Fig. 3) was detected, later confirmed as an EWSR1-ATF1 t(12;22) translocation by next-generation sequencing. Therefore, a malignant gastrointestinal neuroectodermal tumor (GNET) diagnosis was made, also supported by the suspicion of a primary digestive tumor at the stomach. In addition, upon our assessment, the patient presented with a new recurrence in the cervical surgical field. A positron emission tomography – computed tomography (PET-CT) scan in January 2020 confirmed a left laterocervical tumor with signs of neoplastic activity, which was consistent with local relapse.

Upon the assessment of the multidisciplinary tumor board, it was decided that the patient undergo induction chemotherapy with doxorubicin 75 mg/m<sup>2</sup> and ifosfamide 9 mg/m<sup>2</sup> every 3 weeks. After confirming a radiological response in the PET-CT following 6 cycles in May 2020, surgical resection of the cervical mass was performed (July 15th, 2020). Surgery was followed by adjuvant radiotherapy (50 Gy) from September 2nd until October 6th, 2020. A postoperative CT scan showed no tumor activity. Due to the absence of gastric lesions on preoperative PET-CT, endoscopic ultrasound, and postoperative CT scan, close surveillance was planned.

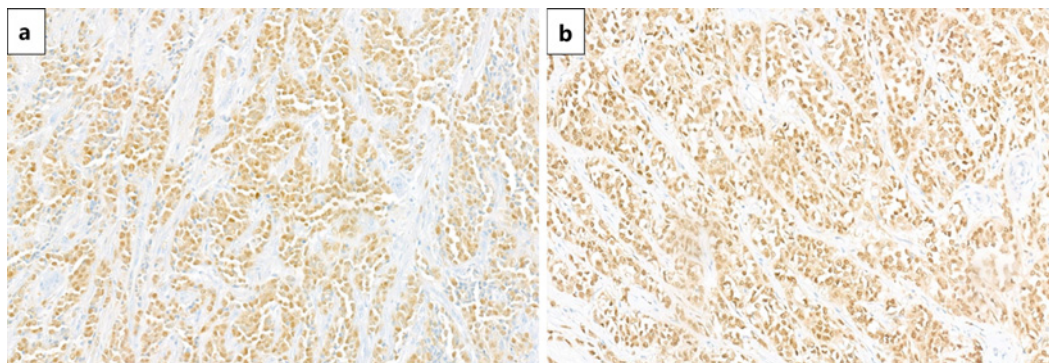
However, in March 2021, the patient presented with a tumor relapse at the right thigh, gluteus, and paravertebral lumbar area. A new biopsy of the right thigh mass was performed, and a 2nd line of systemic treatment with gemcitabine 1,800 mg/m<sup>2</sup> and dacarbazine 500 mg/m<sup>2</sup> every 2 weeks was started, in April 2021. After four cycles, further progression of the disease was observed on a CT scan.

In August 2021, a 3rd line of treatment with carboplatin AUC 5 and etoposide 100 mg/m<sup>2</sup> days 1, 2, and 3 every 3 weeks was started up to 6 cycles. The CT scan in October 2021 demonstrated stabilization of the disease. However, in January 2022, the patient presented growth of tumor implants in the left supraclavicular region, lumbar paravertebral area, and left gluteal musculature. At this time, the case was reviewed again by the multidisciplinary tumor board. The biopsy performed in March 2021 was reviewed, and due to the clinical evolution, a shift of diagnosis was made to CCS because of the absence of a primary gastrointestinal tumor.

In February 2022, a 4th line of treatment with pazopanib 800 mg once daily was started, but the patient presented with disease progression in April 2022. The tumor showed a progression, mainly of the cervical mass, which later became infected, causing intense pain to the patient. On May 15th, 2022, a 5th line of treatment with trabectedin 1.5 mg/m<sup>2</sup> as a continuous infusion over 24 h once every 3 weeks was started. After two cycles, the patient presented cervical pain amelioration, despite a slight growth of the lumbar paravertebral and left gluteal muscular implants noted on the CT scan (July 2022), and, thus, treatment with trabectedin was continued. After five cycles, a CT scan (September 2022) showed a slight decrease in the size of multiple muscular implants. The following CT scan after eight cycles (December 2022) demonstrated a partial response, which lasted until 10 months when the progression disease was confirmed (Fig. 4).

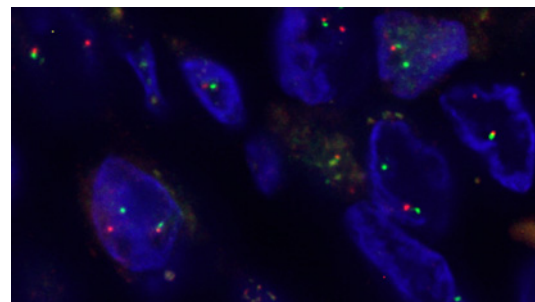


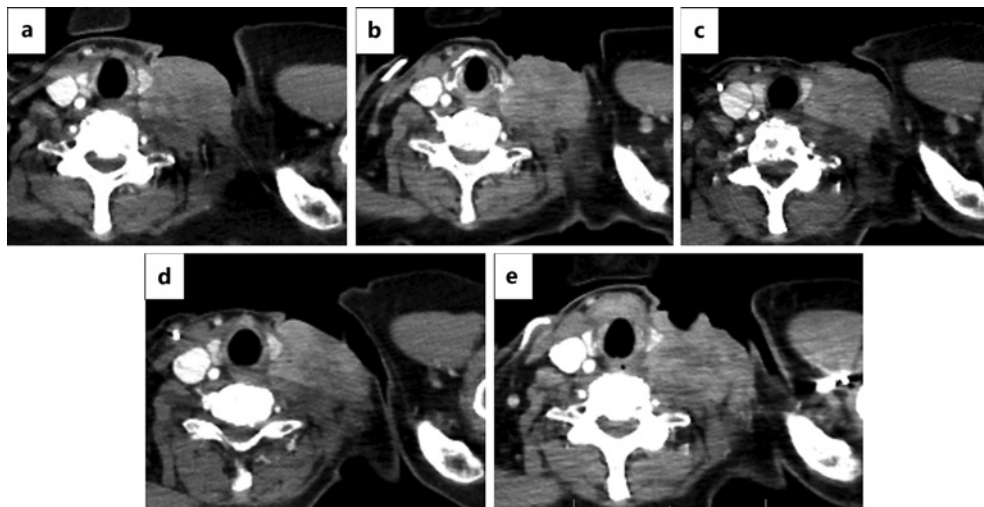
**Fig. 1.** Anatomical pathology samples of hematoxylin-eosin staining. **a** Tumor well demarcated with well-defined borders, not encapsulated (hematoxylin-eosin staining.  $\times 2$ ). **b** Oval cells with a clear eosinophilic and poorly demarcated cytoplasm. The cells present oval nuclei, with isomorphous thin chromatin and eosinophilic micronuclei. The cells are growing in nests, separated by thin fibrous tracts (hematoxylin-eosin staining.  $\times 10$ ).



**Fig. 2.** Immunohistochemistry staining is diffusely positive for S100 (**a**) and SOX10 (**b**).

**Fig. 3.** Translocation of EWSR1 was detected by fluorescence in situ hybridization. XL EWSR1 BA (Break Apart Probe, D-5096-100-OG) consists of an orange-labeled probe hybridizing proximal to the EWSR1 gene region at 22q12.1-12.2 and a green-labeled probe hybridizing distal to the EWSR1 gene region at 22q12.2.





**Fig. 4.** Cervical CT scans with intravenous contrast. **a** Radiological image of the cervical mass before trabectedin was started. Cervical mass of 5 cm × 5.4 cm (April 2022). **b** After 2 cycles with trabectedin. Cervical mass of 5.2 cm (4% increase over baseline) (July 2022). **c** After 6 cycles of trabectedin were administered. Cervical mass of 3.5 cm (30% decrease over baseline) (September 2022). **d** Partial response after 8 cycles of treatment with trabectedin was confirmed. Cervical mass of 3 cm (40% decrease over baseline) (December 2022). **e** Progression disease 10 months later. Cervical mass of 5.5 cm (83.3% increase over baseline) (February 2022).

## Discussion

We present a case of CCS, an ultra-rare sarcoma. The diagnosis of CCS may be difficult, and it is made by pathological examination as well as molecular and cytogenetic studies on biopsy [2, 15]. Because this entity frequently shows melanocytic differentiation, the main differential diagnosis is made with malignant melanoma. In this case, after the first anatomopathological review was performed when the patient was admitted, the detection of the translocation EWSR1-ATF1 t(12; 22) by next-generation sequencing established a clear distinction between CCS and malignant melanoma. No BRAF mutation was detected by Idylla™ BRAF Mutation Test (CE-IVD). A differential diagnosis with GNET was also made. GNET is similar to CCS, as the genetic and neuroectodermal markers are the same. The GNET and CCS tumor cells are characteristically composed of epithelioid, polygonal, or round cells with eosinophilic cytoplasm and vesicular nuclei with prominent nucleoli. However, multinucleated osteoclast-like giant cells have been reported to occur in 50% of GNET cases. Such cells can help in distinguishing GNET from CCS, and we did not find any osteoclast-like giant cells in the present case [16, 17]. Another difference is that melanocytic marker staining are usually positive for CCS (up to 60% for Melan-A and 70% for HMB45) as opposed to GNET, where they are negative [18]. Although this case was negative for three melanocytic marker staining (such as Melan-A, HMB45, and MITF), which is less common but still possible, in conjunction with the lack of a primary gastrointestinal tumor at the endoscopic ultrasound, PET-CT, and CT scans, led to a CCS diagnosis.

Historically, complete surgical resection has been the mainstay of treatment of localized CCS, with or without radiation. The role of adjuvant chemotherapy is unclear [19]. However, CCS is an aggressive sarcoma. Despite optimal management of localized disease, a high proportion of patients develop metastatic disease. The estimated 5-year disease-specific survival is 62–67% [20]. Because CCS is usually not sensitive to conventional chemotherapy [21], the optimal systemic chemotherapy regimen has not been established and must be individualized for patients with locally advanced or metastatic CCS.

After an early and aggressive local recurrence and before the correct anatomopathological diagnosis was made, our patient received chemotherapy with a combination of doxorubicin and ifosfamide [22], facilitating a salvage surgery. The response to doxorubicin-based chemotherapies has been only described as low, according to other published series, such as the retrospective series of 55 patients of A. Smrke et al. [6], with a partial response of 12% (4/34) and stable disease of 44% (15/34) of the patients. However, our patient presented with a partial response that allowed surgical salvage of the disease, and it provides an example of how CCS patients can sometimes respond to traditional chemotherapy such as doxorubicin-ifosfamide chemotherapy.

When metastatic spread occurred, the patient received the combination of gemcitabine and dacarbazine. Gemcitabine is commonly used in managing sarcomas as second- or latter-line treatment, particularly as gemcitabine-based combined chemotherapy [23]. The gemcitabine and dacarbazine combination has been assessed in one non-randomized phase II trial [24] and one non-comparative randomized phase II trial [25] over dacarbazine alone and showed superior progression-free survival (PFS) and overall survival (OS) [26]. After the development of refractory or relapsed disease, the treatment options are limited, and the combination of carboplatin and etoposide is a treatment option after standard therapy [27].

When the CCS diagnosis was made, treatment with pazopanib, an oral inhibitor targeting both VEGFR and platelet-derived growth factor receptor (PDGFR), was attempted without response. Pazopanib is a treatment option for these tumors due to its significant angiogenic activity. This drug has been demonstrated to be a treatment option for patients with metastatic non-adipocytic soft tissue sarcoma [28, 29].

CCS is one of the 20% of soft tissue sarcoma subtypes in which specific chromosomal translocations are observed. The activity of trabectedin has been explored in these translocation-related sarcoma subtypes due to its ability to bind to DNA and displace transcription factors, demonstrating disease control in some cases [10–13]. In addition to its activity in this type of sarcoma, it is important to highlight the results of a post hoc analysis showing that trabectedin has anti-tumorigenic activity in some rare or ultra-rare soft tissue sarcomas. This case series shows that in some ultra-rare and other rare sarcomas, particularly translocation-related sarcomas, the use of trabectedin may have some antitumor activity with a known and manageable safety profile, in a similar way as seen in this patient [10].

Furthermore, our patient presented with a suspicion of radiological progression after two cycles of trabectedin, which was ruled out after three cycles more. Some reviews have suggested that radiological patterns of response to trabectedin are different with some atypical responses associated with clinical improvement [29, 30]. In addition, the preclinical study by Nakai et al. [14] demonstrated that trabectedin decreased the cell proliferation of five CCS cell lines in a dose-dependent manner in vitro and reduced tumor growth of two mouse xenograft models. Moreover, investigators observed that trabectedin induced G2/M cell cycle arrest and apoptosis in CCS cell lines, which might indicate that trabectedin is a promising differentiation-inducing agent for CCS.

The clinical evidence for trabectedin is stronger in other types of sarcomas. Several phase II studies evaluating trabectedin treatment in patients with soft tissue sarcoma showed a response rate of 7–17% and an increase in PFS of 20–29% [31–35]. In addition, a phase III trial observed the superiority of trabectedin over dacarbazine in patients with advanced liposarcoma or leiomyosarcoma who had been refractory to anthracyclines and at least one additional systemic therapy. Although OS, the primary endpoint, recorded a 13% reduction in the risk of death with trabectedin (median OS for trabectedin vs. dacarbazine, 13.7 vs. 13.1 months; hazard ratio, 0.93;  $p = 0.49$ ), this was not statistically significant. PFS in the trabectedin arm produced a 45% reduction in the risk of disease progression or death (median PFS for trabectedin vs. dacarbazine, 4.2 vs. 1.5 months; hazard ratio, 0.55;  $p < 0.001$ ) [36, 37].

## Conclusion

To the best of our knowledge, this is the first report of a CCS treated with trabectedin that resulted in a partial response. This case suggests that trabectedin is a potential therapeutic option in aggressive metastatic CCS, having seen our patient achieve a clinical and radiological tumor response after four prior lines of treatment. With our experience, we suggest that more studies could be performed using trabectedin treatment in advanced CCS patients so as to justify trabectedin as a novel differentiation therapeutic agent for these patients.

## Acknowledgment

Authors express gratitude to Meisys (Madrid, Spain) for writing assistance.

## Statement of Ethics

This retrospective review of patient data did not require ethical approval in accordance with local/national guidelines. The authors state that they have followed the principles outlined in the Declaration of Helsinki for all human or animal experimental investigations. Written informed consent was obtained from the patient for publication of the details of their medical case and any accompanying images.

## Conflict of Interest Statement

Mar Galera has participated as a speaker for PharmaMar and MSD, and she has received support for attending meetings and/or travel from PharmaMar, MSD, Lilly, and Roche. Rosa Álvarez has received consulting fees from AstraZeneca, PharmaMar, Boehringer, Novartis, Sanofi, and GSK. She has also participated as a speaker for PharmaMar, and she has received travel funds from Roche and PharmaMar. She has received research funding from PharmaMar, Rain Therapeutics, GSK, Boehringer, Cebiotex, Roche, Philogen, MSD, Janssen, Pfizer, Daiichi, Gilead, and Seagen. Marta Arregui has participated as a speaker for Roche, and she has received support from PharmaMar for attending meetings and/or travel. She has also been coordinating principal investigator with Lilly. Ana Álvarez has participated as a speaker for PharmaMar and as principal investigator for Merck. Natalia Gutierrez has participated as a speaker for MSD and AstraZeneca, and she has received support for attending meetings and/or travel from MSD, Angelini, Pierre Fabre, Rovi, Amgen, and Pfizer. Antonio Calles has received honoraria from AstraZeneca, Boehringer Ingelheim, Bayer, Pfizer, Roche, Novartis, Merck Sharp & Dohme, and Bristol Myers Squibb. He has a consulting or advisory role with AstraZeneca, Amgen, Boehringer Ingelheim, Pfizer, Roche/Genentech, Eli Lilly and Company, Novartis, Takeda, Merck Sharp & Dohme, and Bristol Myers Squibb. He has received research funding from Merck Sharp & Dohme. He has received support for attending meetings and/or travel from Roche, Pfizer, Boehringer Ingelheim, Merck Sharp & Dohme, and Bristol Myers Squibb. Carolina Agra has received support for attending meetings and/or travel from PharmaMar. The other authors declare that they have no conflicts of interest.

## Funding Sources

This research was funded by PharmaMar, S.A.

## Author Contributions

M.G., R.A., M.A., M.P., A.A., R.A.G.C., A.D., N.G., A.C., and C.A. made substantial contributions to the conception or design of the work and acquisition, analysis, and interpretation of the data. All authors also contributed to the drafting and critical review of the content, approved the final version to be published, and are accountable for all aspects of the work.

## Data Availability Statement

All data generated or analyzed during this study are included in this article. Further inquiries can be directed to the corresponding author.

## References

- 1 Antonescu CR, Tschernyavsky SJ, Woodruff JM, Jungbluth AA, Brennan MF, Ladanyi M. Molecular diagnosis of clear cell sarcoma: detection of EWS-ATF1 and MTF-M transcripts and histopathological and ultrastructural analysis of 12 cases. *J Mol Diagn*. 2002;4(1):44–52.
- 2 Panza E, Ozenberger BB, Straessler KM, Barrott JJ, Li L, Wang Y, et al. The clear cell sarcoma functional genomic landscape. *J Clin Invest*. 2021;131(15):e146301.
- 3 Dim DC, Cooley LD, Miranda RN. Clear cell sarcoma of tendons and aponeuroses: a review. *Arch Pathol Lab Med*. 2007;131(1):152–6.
- 4 Zucman J, Delattre O, Desmaze C, Epstein AL, Stenman G, Speleman F, et al. EWS and ATF-1 gene fusion induced by t(12;22) translocation in malignant melanoma of soft parts. *Nat Genet*. 1993;4:341–5.
- 5 Mavrogenis A, Bianchi G, Stavropoulos N, Papagelopoulos P, Ruggieri P. Clinicopathological features, diagnosis and treatment of clear cell sarcoma/melanoma of soft parts. *Hippokratia*. 2013;17(4):298–302.
- 6 Smrke A, Frezza AM, Giani C, Somaiah N, Brahmi M, Czarnecka AM, et al. Systemic treatment of advanced clear cell sarcoma: results from a retrospective international series from the World Sarcoma Network. *ESMO Open*. 2022;7(3):100522.
- 7 Wagner AJ, Goldberg JM, DuBois SG, Choy E, Rosen L, Pappo A, et al. Tivantinib (ARQ 197), a selective inhibitor of MET, in patients with microphthalmia transcription factor associated tumors: results of a multicenter phase 2 trial. *Cancer*. 2012;118(23):5894–902.
- 8 Schöffski P, Wozniak A, Stacchiotti S, Rutkowski P, Blay JY, Lindner LH, et al. Activity and safety of crizotinib in patients with advanced clear-cell sarcoma with Met alterations: European Organization for Research and Treatment of Cancer phase II trial 90101 'CREATE'. *Ann Oncol*. 2017;28(12):3000–8.
- 9 D'Incalci M, Galmarini CM. A review of trabectedin (ET-743): a unique mechanism of action. *Mol Cancer Ther*. 2010;9(8):2157–63.
- 10 Palmerini E, Sanfilippo R, Grignani G, Buonadonna A, Romanini A, Badalamenti G, et al. Transcription regulators and ultra-rare and other rare translocation-related sarcomas treated with trabectedin: a proof of principle from a post-hoc analysis. *Front Oncol*. 2022;12:1042479.
- 11 Le Cesne A, Cresta S, Maki RG, Blay JY, Verweij J, Poveda A, et al. A retrospective analysis of antitumour activity with trabectedin in translocation-related sarcomas. *Eur J Cancer*. 2012;48(16):3036–44.
- 12 Kawai A, Araki N, Sugiura H, Ueda T, Yonemoto T, Takahashi M, et al. Trabectedin monotherapy after standard chemotherapy versus best supportive care in patients with advanced, translocation-related sarcoma: a randomised, open-label, phase 2 study. *Lancet Oncol*. 2015;16(4):406–16.
- 13 Takahashi M, Takahashi S, Araki N, Sugiura H, Ueda T, Yonemoto T, et al. Efficacy of trabectedin in patients with advanced translocation-related sarcomas: pooled analysis of two phase II studies. *Oncologist*. 2017;22(8):979–88.
- 14 Nakai T, Imura Y, Tamiya H, Yamada S, Nakai S, Yasuda N, et al. Trabectedin is a promising antitumor agent potentially inducing melanocytic differentiation for clear cell sarcoma. *Cancer Med*. 2017;6(9):2121–30.
- 15 Ibrahim RM, Steenstrup Jensen S, Juel J. Clear cell sarcoma-A review. *J Orthop*. 2018;15(4):963–6.

- 16 Sivasubramaniam P, Tiegs-Heiden CA, Sturgis CD, Hagen CE, Hartley CP, Thangaiah JJ. Malignant gastrointestinal neuroectodermal tumor: cytologic, histologic, immunohistochemical, and molecular pitfalls. *Ann Diagn Pathol*. 2021;55:151813.
- 17 Liu ZL, Zhou B, Zhao YJ, Yu MQ, Liang J, Li Y. A case report of malignant neuroectodermal tumor of the gastrointestinal tract without common gene fusion in a soft tissue tumor. *J Gastrointest Oncol*. 2022;13(3):1489–98.
- 18 Dei Tos AP. *Soft tissue sarcomas: a pattern-based approach to diagnosis*. 1st ed. Cambridge: Cambridge University Press; 2018.
- 19 Clark MA, Johnson MB, Thway K, Fisher C, Thomas JM, Hayes AJ. Clear cell sarcoma (melanoma of soft parts): the Royal Marsden Hospital experience. *Eur J Surg Oncol*. 2008;34(7):800–4.
- 20 Blazer DG 3rd, Lazar AJ, Xing Y, Askew RL, Feig BW, Pisters PWT, et al. Clinical outcomes of molecularly confirmed clear cell sarcoma from a single institution and in comparison with data from the Surveillance, Epidemiology, and End Results registry. *Cancer*. 2009;115(13):2971–9.
- 21 Ray-Coquard I, Serre D, Reichardt P, Martín-Broto J, Bauer S. Options for treating different soft tissue sarcoma subtypes. *Future Oncol*. 2018;14(10s):25–49.
- 22 Judson I, Verweij J, Gelderblom H, Hartmann JT, Schöffski P, Blay JY, et al. Doxorubicin alone versus intensified doxorubicin plus ifosfamide for first-line treatment of advanced or metastatic soft-tissue sarcoma: a randomised controlled phase 3 trial. *Lancet Oncol*. 2014;15(4):415–23.
- 23 Ducoulombier A, Cousin S, Kotecki N, Penel N. Gemcitabine-based chemotherapy in sarcomas: a systematic review of published trials. *Crit Rev Oncol Hematol*. 2016;98:73–80.
- 24 Losa R, Fra J, López-Pousa A, Sierra M, Goitia A, Uña E, et al. Phase II study with the combination of gemcitabine and DTIC in patients with advanced soft tissue sarcomas. *Cancer Chemother Pharmacol*. 2007;59(2):251–9.
- 25 García-Del-Muro X, López-Pousa A, Maurel J, Martín J, Martínez-Trufero J, Casado A, et al. Randomized phase II study comparing gemcitabine plus dacarbazine versus dacarbazine alone in patients with previously treated soft tissue sarcoma: a Spanish Group for Research on Sarcomas study. *J Clin Oncol*. 2011;29(18):2528–33.
- 26 van Maldegem AM, Benson C, Rutkowski P, Blay JY, van den Berg H, Placzke J, et al. Etoposide and carbo or cisplatin combination therapy in refractory or relapsed Ewing sarcoma: a large retrospective study. *Pediatr Blood Cancer*. 2015;62(1):40–4.
- 27 Sleijfer S, Ray-Coquard I, Papai Z, Le Cesne A, Scurr M, Schöffski P, et al. Pazopanib, a multikinase angiogenesis inhibitor, in patients with relapsed or refractory advanced soft tissue sarcoma: a phase II study from the European organisation for research and treatment of cancer-soft tissue and bone sarcoma group (EORTC study 62043). *J Clin Oncol*. 2009;27(19):3126–32.
- 28 van der Graaf WT, Blay JY, Chawla SP, Kim DW, Bui-Nguyen B, Casali PG, et al. Pazopanib for metastatic soft-tissue sarcoma (PALETTE): a randomised, double-blind, placebo-controlled phase 3 trial. *Lancet*. 2012;379(9829):1879–86.
- 29 Taieb S, Saada-Bouزيد E, Tresch E, Ryckewaert T, Bompas E, Italiano A, et al. Comparison of response evaluation criteria in solid tumours and Choi criteria for response evaluation in patients with advanced soft tissue sarcoma treated with trabectedin: a retrospective analysis. *Eur J Cancer*. 2015;51(2):202–9.
- 30 Esser M, Kloth C, Thaiss WM, Reinert CP, Fritz J, Kopp HG, et al. CT-response patterns and the role of CT-textural features in inoperable abdominal/retroperitoneal soft tissue sarcomas treated with trabectedin. *Eur J Radiol*. 2018;107:175–82.
- 31 Huygh G, Clement PM, Dumez H, Schöffski P, Wildiers H, Selleslach J, et al. Ecteinascidin-743: evidence of activity in advanced, pretreated soft tissue and bone sarcoma patients. *Sarcoma*. 2006;2006:56282.
- 32 Garcia-Carbonero R, Supko JG, Manola J, Seiden MV, Harmon D, Ryan DP, et al. Phase II and pharmacokinetic study of ecteinascidin 743 in patients with progressive sarcomas of soft tissues refractory to chemotherapy. *J Clin Oncol*. 2004;22(8):1480–90.
- 33 Garcia-Carbonero R, Supko JG, Maki RG, Manola J, Ryan DP, Harmon D, et al. Ecteinascidin-743 (ET-743) for chemotherapy-naïve patients with advanced soft tissue sarcomas: multicenter phase II and pharmacokinetic study. *J Clin Oncol*. 2005;23(24):5484–92.
- 34 Le Cesne A, Blay JY, Judson I, Van Oosterom A, Verweij J, Radford J, et al. Phase II study of ET-743 in advanced soft tissue sarcomas: a European Organisation for the Research and Treatment of Cancer (EORTC) soft tissue and bone sarcoma group trial. *J Clin Oncol*. 2005;23(3):576–84.
- 35 Demetri GD, Chawla SP, von Mehren M, Ritch P, Baker LH, Blay JY, et al. Efficacy and safety of trabectedin in patients with advanced or metastatic liposarcoma or leiomyosarcoma after failure of prior anthracyclines and ifosfamide: results of a randomized phase II study of two different schedules. *J Clin Oncol*. 2009;27(25):4188–96.
- 36 Demetri GD, von Mehren M, Jones RL, Hensley ML, Schuetz SM, Staddon A, et al. Efficacy and safety of trabectedin or dacarbazine for metastatic liposarcoma or leiomyosarcoma after failure of conventional chemotherapy: results of a phase III randomized multicenter clinical trial. *J Clin Oncol*. 2016;34(8):786–93.
- 37 Patel S, von Mehren M, Reed DR, Kaiser P, Charlson J, Ryan CW, et al. Overall survival and histology-specific subgroup analyses from a phase 3, randomized controlled study of trabectedin or dacarbazine in patients with advanced liposarcoma or leiomyosarcoma. *Cancer*. 2019;125(15):2610–20.